


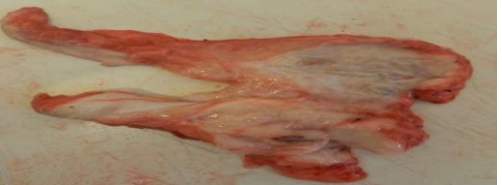




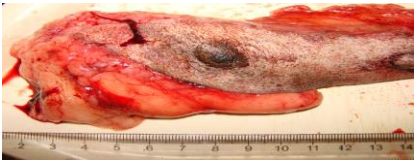







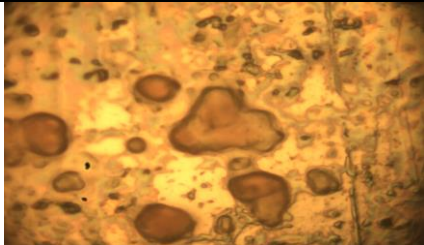


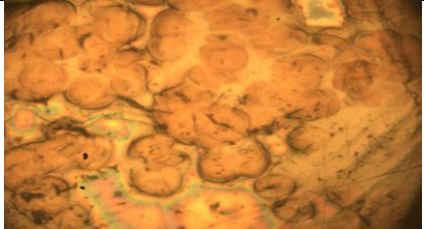

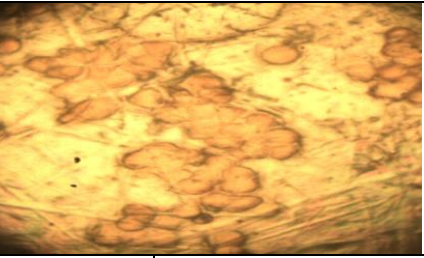


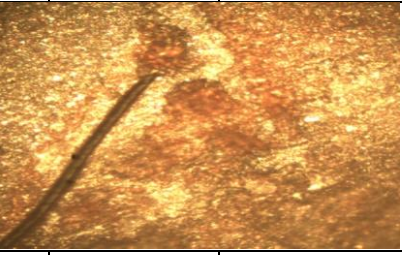


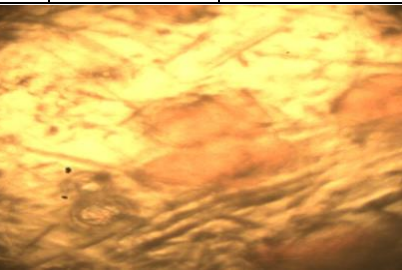










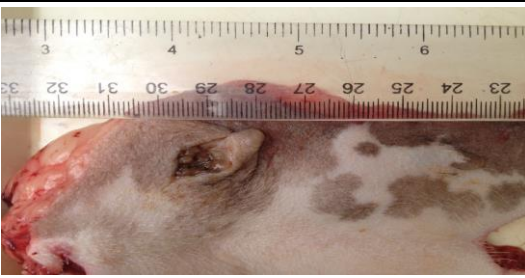

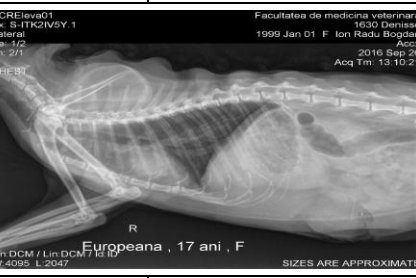

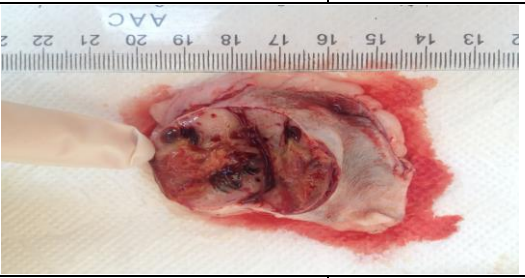







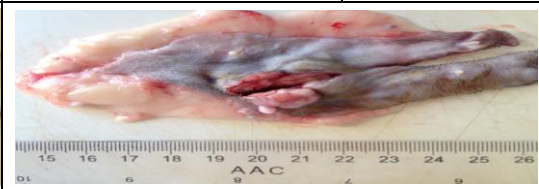










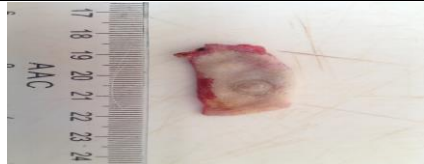
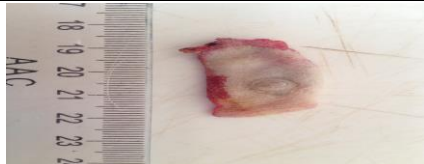




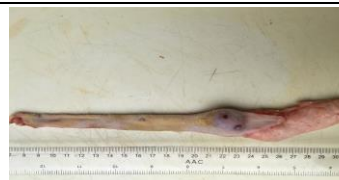

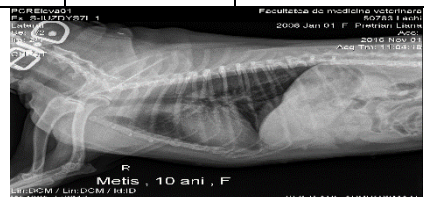
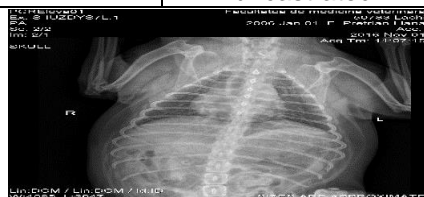






Nr. Ctr	SERS Diagnosis		Receiving date	Animal identification	Cytological Diagnosis (Prof. Univ. Dr. Militaru Manuella)	Histological Diagnosis (Prof. Univ. Dr. Militaru Manuella)	Surgeon
	Tumour	Margin					
1	Malignant	Possible contamination	30/10/2014	Canine, German shepherd, F, 3 years old, uncastrated	Suspected benign tumour hyperplasia	Secretory adenosis (lobular hyperplasia)	Dr Togoe Dorin
							
2	Malignant	Possible contamination	03/12/2014	Mixed breed dog, F, 15 years old, unsterilised	Suspected breast carcinoma	Solid and tubulo papillary breast carcinoma	Dr. Togoe Dorin
							
3	Malignant	Possible contamination	03/12/2014	Cocker dog, F, 11 years old, unsterilised	Suspected breast adenocarcinoma	Tubulo papillary breast carcinoma and lobular hyperplasia (adenosis)	Dr. Togoe Dorin
							
4	Malignant	Possible contamination	12/12/2014	Common European feline, F, 14 years old, sterilised	Suspected breast carcinoma	Cribriform breast carcinoma	Dr. Vițalariu Alexandru
							













5	Missing sample	Missing margin	16/12/2014	Common European feline, F, 15 years old, sterilised	Suspected breast carcinoma	Tubulo papillary carcinoma	Dr. Togoe Dorin
6	Missing sample	Missing margin	19/12/2014	Canine, Bulldog, F, 11 years old, sterilised	Suspected breast carcinoma	Mixed breast carcinoma	Dr. Vitalaru Alexandru
7	Missing sample	Missing margin	19/12/2014	Canine, Golden Retriever, F, 11 years old, sterilised	Suspected breast carcinoma	Tubular common breast carcinoma with lymph nodal methastasis	Dr. Vitalaru Alexandru
8	Malignant	Possible contamination	13/01/2015	Canine, Boxer, F, 9,5 years old, unsterilised	Suspected breast carcinoma	Mixed benign tumour	Dr. Togoe Dorin
							
9	Malignant	Possible contamination	21/01/2015	Norwegian cat, F, 11 years old, sterilised	Suspected breast carcinoma	Cribriform common breast carcinoma	Dr. Togoe Dorin
-				-		-	
10	Malignant	Possible contamination	23/03/2015	Canine, Alsatian shepherd, F, 10 years old, unsterilised	Suspected breast carcinoma	Mixed breast carcinoma	Dr. Birtoiu Alin








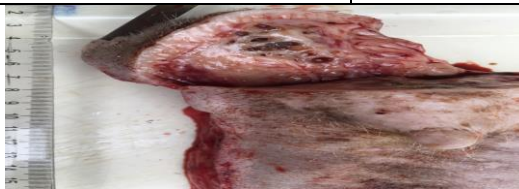








							
11	Missing sample	Possible contamination	20/11/2015	Mixed breed dog, F, 13 years old, unsterilised	Suspected breast carcinoma	Papilliferous, solid and lobular common breast carcinoma	Dr. Birtoiu Alin
							
12	Missing sample	Missing margin	23/03/2016	Bichon dog, F, 14 years old, neutered	Suspected breast carcinoma	Mixed breast carcinoma	Dr. Birtoiu Alin
13	Malignant	Possible contamination	14/04/2016	Mixed breed dog, F, 11 years old, unsterilised	Suspected breast carcinoma and malignant myoepithelioma	Benign glandular hyperplasia - secretory adenosis	Dr. Togoe Dorin
							
14	unclear	Possible contamination	16/09/2016	Common European feline, F, 11 years old	Suspected common breast carcinoma	Breast comedocarcinoma	Dr. Vițălaru Alexandru
















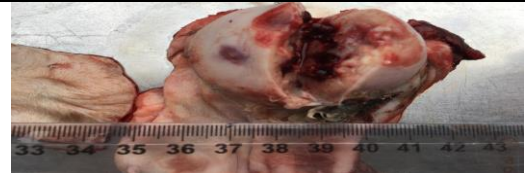
				15	Malignant	Possible contamination	21/09/2016	Teckel mixed breed dog, F, 8 years old, uncastarted	Suspected complex mammary adenocarcinoma. Suspected lobular mammary hyperplasia	Tubulo papillary common breast carcinoma	Dr. Țogoe Dorin
				16	Malignant	Possible contamination	27/09/2016	Common European feline, F, 17 years old, sterilised	Suspected low malignancy breast carcinoma	Solid common breast carcinoma	Dr. Vitalaru Alexandru
				17	Malignant	Contamination	29/09/2016	Cocker Spaniel dog, F, 15 years old, sterilised	Suspected breast adenocarcinoma	Mixed breast carcinoma with malignant myoepithelioma areas	Dr. Țogoe Dorin








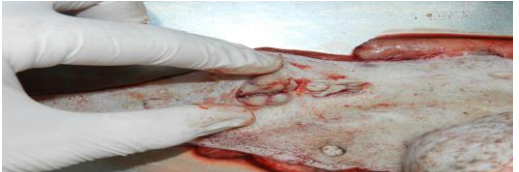



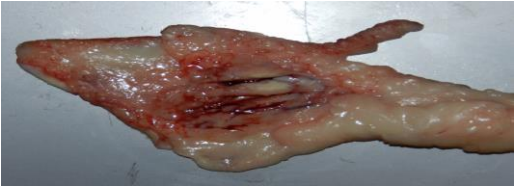
							
18	Malignant	Unclear	29/09/2016	Common European feline, F, 14 years old, unsterilised	Suspected breast carcinoma	Cribriform common breast carcinoma	Dr. Țogoe Dorin
							
19	Malignant	Contamination	29/09/2016	Common European feline, F, 9 years old, sterilised	Suspected breast adenocarcinoma	Cribriform common breast carcinoma	Dr. Țogoe Dorin
							
20	Malignant	Clean	04/10/2016	Mixed breed dog, F, 12 years old, uncastrated	Suspected breast adenocarcinoma	Mammary fibroadenoma associated with a core of tubular common breast carcinoma, with markedly inflammatory reaction.	Dr. Vitalaru Alexandru
							



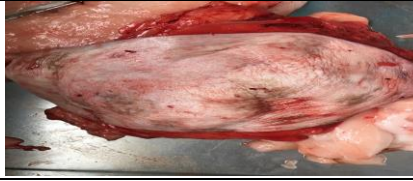




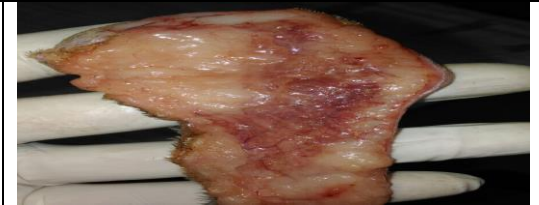



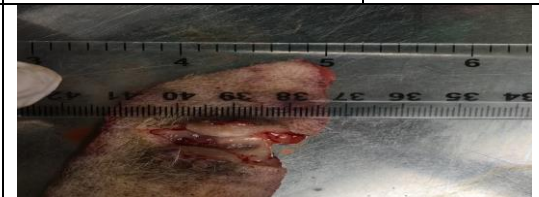


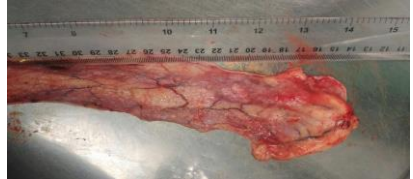
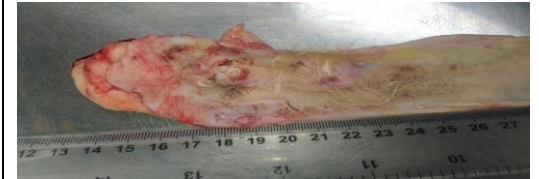
21	Benign	Unclear	07/10/2016	Yorkshire Terrier dog, F, 7 years old, sterilised	Cytomorphological characteristics suggest a benign breast epithelial tumour	Duct ectasia associated with lobular breast hyperplasia (benign lesions)	Dr. Diaconescu Alexandru
							
22	Malignant	Possible contamination	27/10/2016	Common European feline, F, 10 years old, sterilised	Suspected breast carcinoma	Tubulo papillary common breast carcinoma	Dr. Diaconescu Alexandru
							
23	Malignant	Possible contamination	01/11/2016	Mixed breed dog, 10 years old, uncastrated	Suspected breast adenocarcinoma	Mixed breast carcinoma	Dr. Ţogoe Dorin
							
24	Malignant	Possible contamination	09/11/2016	Cocker Spaniel dog, F, 12 years old, neuter	Suspected breast cancer of low malignancy.	Solid common breast carcinoma	Dr. Diaconescu Alexandru
							

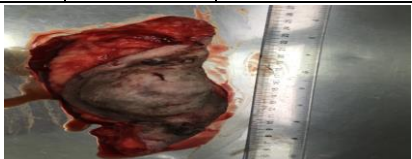
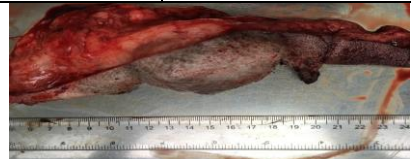












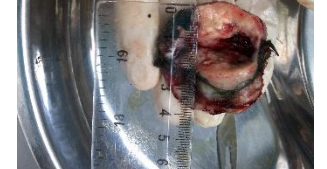
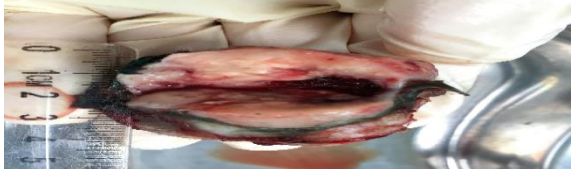
Nr. Ctr	SERS Diagnosis		Receiving date	Animal identification	Cytological Diagnosis (Prof. Univ. Dr. Militaru Manuella)	Histological Diagnosis (Prof. Univ. Dr. Militaru Manuella)	Surgeon
	Tumor	Margin					
25	Malignant	Clean	15/11/2016	Common European Feline, F, 15 years old, neutered.	Suspected breast cancer.	Common breast carcinoma, tubulo-papillary type.	Dr Diaconescu Alexandru
 <p>PCRElev01 Ex: S-ITYBAJUI 1 Lateral Se: 1/2 Im: 2/1 CHEST R Europeana, 15 ani, F Lin DCM / Lin DCM / Id ID W:4095, L:2047 SIZES ARE APPROXIMATE</p>		 <p>PCRElev01 Ex: S-ITYBAJUI 1 Dorso-ventral Se: 2/2 Im: 2/1 SKULL R L Europeana, 15 ani, F Lin DCM / Lin DCM / Id ID W:4095, L:2047 SIZES ARE APPROXIMATE</p>					
26	Malignant	Possible contamination	23/11/2016	Birman cat, F, 15 years old, uncastrated.	Suspected breast adenocarcinoma.	Breast comedocarcinoma.	Dr. Vitalaru Alexandru
 <p>PCRElev01 Ex: S-ITYBAJUI 1 Lateral Se: 1/1 Im: 2/1 CHEST R Birmaneza, F Lin DCM / Lin DCM / Id ID W:4095, L:2047 SIZES ARE APPROXIMATE</p>							
27	Malignant	Clean	05/12/2016	Common European Feline, F, 13 years old, neutered.	Suspected breast carcinoma.	Cribriform Breast carcinoma.	Dr. Vitalaru Alexandru
							




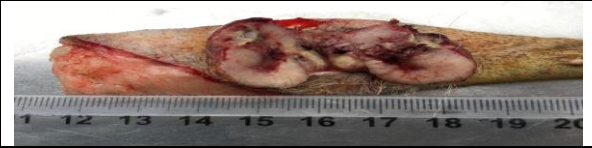




28	Malignant	Clean	06/12/2016	Deutsche Bracke, F, 12 years old, neutered.	Common breast carcinoma (M2), squamous cell skin carcinoma (M3-M4).	M2 -mixed breast carcinoma; M3 – M4 - squamous cell skin carcinoma.	Dr. Togoe Dorin
							
29	Malignant	Possible contamination	07/12/2016	Samoyed dog, F, 8 years old, uncastrated.	Common breast carcinoma.	Mammary anaplastic carcinoma.	Dr. Togoe Dorin
							
30	Malignant	Clean	09/12/2016	Mixed breed dog, F, 7 years old, neutered.	Suspected mixed breast carcinoma.	Tubulo-papillary common breast carcinoma.	Dr. Diaconescu Alexandru
							
31	Malignant	Missing margin	09/12/2016	Field Spaniel dog, F, 14 years old, uncastrated.	Suspected Myoepithelial Carcinoma.	Myoepithelial Carcinoma.	Dr. Vitalaru Alexandru
							
32	Malignant	Missing margin	16/12/2016	Caniche dog, F, 12 years old, neutered.	Unfulfilled	Secretory breast carcinoma.	Dr. Togoe Dorin

Nr Crt	SERS Diagnosis		Receiving date	Animal identification	Cytological Diagnosis (Prof. Univ. Dr. Militaru Manuella)	Histological Diagnosis (Prof. Univ. Dr. Militaru Manuella)	Surgeon
	Tumour	Margin					
35	Malignant	Possible contamination	06.01.2017	Birman cat, F, 14 years old, neutered.	Unfulfilled.	Solid common breast carcinoma.	Dr. Diaconescu Alexandru
							
36	Malignant	Possible contamination	30.01.2017	Labrador dog, F, 13 years old, uncastrated.	Suspected breast adenocarcinoma.	Tubulo papillary carcinoma.	Dr. Vițălaru Alexandru
							
37	Malignant	Possible contamination	01.02.2017	Pekingese dog, F, 8 years old, uncastrated.	Malignant epithelial tumour, breast adenocarcinoma.	Invasive micropapillary carcinoma.	Dr. Diaconescu Alexandru
							
38	Benign left side, Malignant right side.	Clean	02.02.2017	Common European feline, F, 15 years old, uncastrated.	Malignant epithelial tumour, breast adenocarcinoma.	Breast comedocarcinoma.	Dr. Vitalaru Alexandru
							

39	Malignant	Clean	07.02.2017	Common European feline, F, 7 years old, neutered.	Benign tumour formation-mammary gland adenoma.	Lobular secretory hyperplasia and ductal ectasia with eosinophilic intraluminal product.	Dr. Diaconescu Alexandru
							
39 - 1	Malignant	Possible contamination	10.02.2017	German Shepherd dog, F, 7 years old, uncastrated.	-	-	Dr. Bîrțoiu Alin
-		-		-		-	
40	Malignant	Possible contamination	03.03.2017	Bichon dog, F, 12 years old, Neutered.	Mammary gland adenocarcinoma with possible squamous differentiation.	Solid and tubulo papillary common breast carcinoma	Dr. Vitalaru Alexandru
							
41	Malignant	Possible contamination	16.03.2017	Birman cat, 12 years old, uncastrated.	Mammary gland adenoma.	Cribriform breast carcinoma.	Dr. Diaconescu Alexandru
							

42	Malignant	Possible contamination	05.04.2017	Mixed breed dog, F, 13 years old, neutered.	Reactive lymphoid hyperplasia.	Lipoma.	Dr. Țogoe Dorin
							
43	Malignant	Possible contamination	03.05.2017	Common European feline, F, 14 years old, neutered.	-	Intraductal papillary adenoma	Dr. Diaconescu Alexandru
							
44	Malignant	Possible contamination	08.05.2017	German shepherd dog, M, 13 years old, neutered	-	Tubulo-papillary common breast adenocarcinoma with cribriform areas.	Dr. Vițălaru Alexandru
							
45	Malignant	Possible contamination	09.05.2017	Birman cat, F, 10 years old,-	-	Solid and tubulo-papillary common breast adenocarcinoma	Dr. Vițălaru Alexandru
							

Nr. Crt	SERS Diagnosis		Receiving date	Animal identification	Cytological Diagnosis (Prof. Univ. Dr. Militaru Manuella)	Histological Diagnosis (Prof. Univ. Dr. Militaru Manuella)	Surgeon
	Tumour	Margin					
46	Malignant	Possible contamination	26.05.2017	German shepherd dog, F, 10 years old, uncastrated	-	Complex carcinoma.	Dr. Țogoe Dorin
							
47	Malignant	Possible contamination	29.06.2017	Common European feline, F, 9 years old, neutered	-	Tubular common carcinoma.	Dr. Diaconescu Alexandru
							
48	Malignant	Possible contamination	04.07.2017	German Shorthaired Pointer dog, F, 9 years old, uncastrated	-	Tubulo- papillary common carcinoma and lymph nodal metastasis.	Dr. Țogoe Dorin
							
49	Malignant	Possible contamination	04.07.2017	Common European feline, F, 15 years old, neutered	-	Solid, common breast carcinoma	Dr. Diaconescu Alexandru
							

50	Malignant	Possible contamination	25.07.2017	Mixed breed dog, F, 10 years old, F,sterilized	-	-	Dr. Țogoe Dorin
							
51	Unclear	Unclear	07.08.2017	Parson Jack Russel, dog, F, 9 Years old, unsterilized	-	Fibroadenoma	Dr. Vițălaru Alexandru
							
52	Malignant		04.09.2017	Mixed breed dog, F, 11 Years old, unsterilized	-	-	Dr. Țogoe Dorin
